Anatomic landmarks for emergency cricothyrotomy

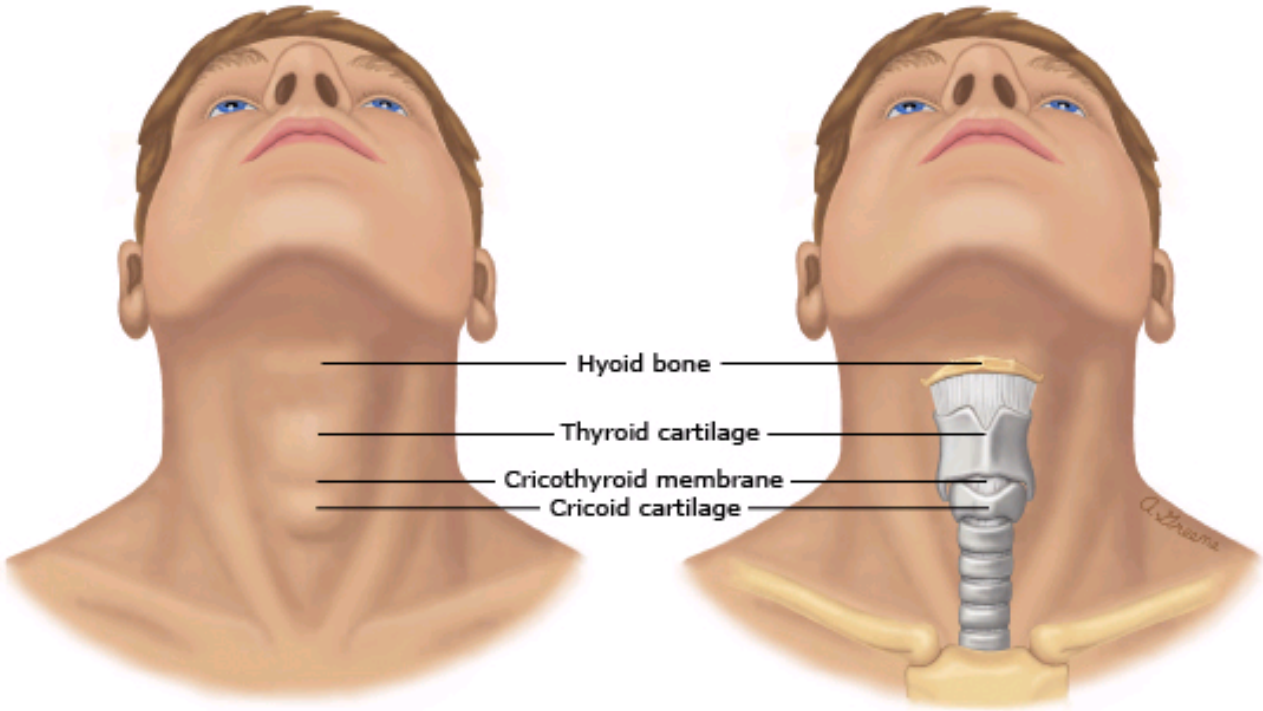

Understanding of the local anatomy is critical to the performance of cricothyrotomy. The laryngeal prominence forms the superior edge of the thyroid cartilage, where there is often a prominent, palpable "V-shaped" notch. The vocal cords are housed within and protected by the thyroid cartilage. The hyoid bone lies cephalad to the thyroid cartilage and in patients where the thyroid cartilage is not prominent it can be mistaken for the thyroid prominence. The cricoid cartilage is a complete cartilaginous ring located caudal to the thyroid cartilage. The cricothyroid membrane lies between the thyroid and cricoid cartiages.

UpToDate®

Copyrights apply

Cricothyroidotomy equipment

Equipment

A. Scalpel-No. 11 blade
B. Trousseau dilator
C. Tracheal hook
D. 10-cc syringe
E. Tracheostomy tube (No. 4 or 6 Shiley, cuffed)
F. Obturator
G. Inner cannula
H. Circumferential tie
I. Bag-valve-mask and ventilator tubing

Reproduced with permission from: Custalow, CB. Color Atlas of Emergency Department Procedures, Elsevier Saunders, Philadelphia 2005. Copyright ©2005 Elsevier.

UpToDate®

Copyrights apply

Standard cricothyrotomy step one

Immobilize the larynx and palpate the cricothyroid membrane with the index finger of the non-dominant hand.

Reproduced with permission from: Custalow CB. Color Atlas of Emergency Department Procedures, Elsevier Saunders, Philadelphia 2005. Copyright ©2005 Elsevier.

UpToDate®

Copyrights apply

Standard cricothyrotomy step two

Make a midline vertical skin incision, 3-5 cm in length.

Reproduced with permission from: Custalow CB. Color Atlas of Emergency Department Procedures, Elsevier Saunders, Philadelphia 2005. Copyright ©2005 Elsevier.

UpToDate®

Copyrights apply

Standard cricothyrotomy step three

Incise the cricothyroid membrane transversely.

Reproduced with permission from: Custalow CB. Color Atlas of Emergency Department Procedures, Elsevier Saunders, Philadelphia 2005. Copyright ©2005 Elsevier.

UpToDate®

Copyrights apply

Standard cricothyrotomy step four

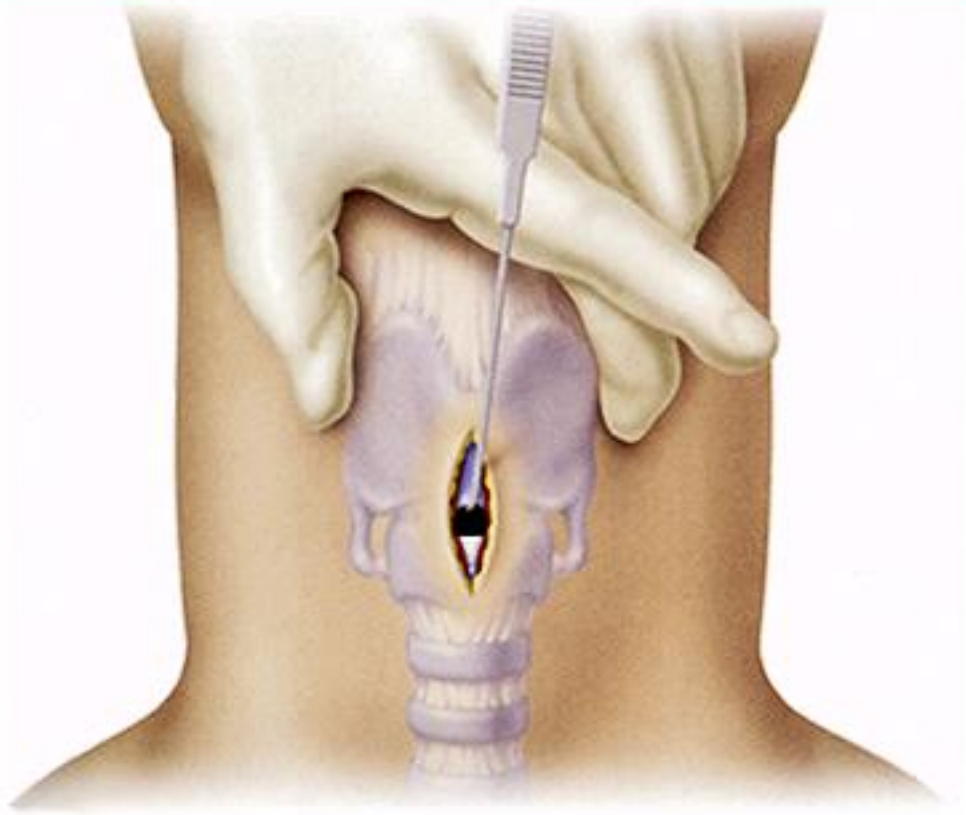

Insert the tracheal hook and ask an assistant to provide upward traction.

Reproduced with permission from: Custalow CB. Color Atlas of Emergency Department Procedures, Elsevier Saunders, Philadelphia 2005. Copyright ©2005 Elsevier.

UpToDate®

Copyrights apply

Standard cricothyrotomy step five

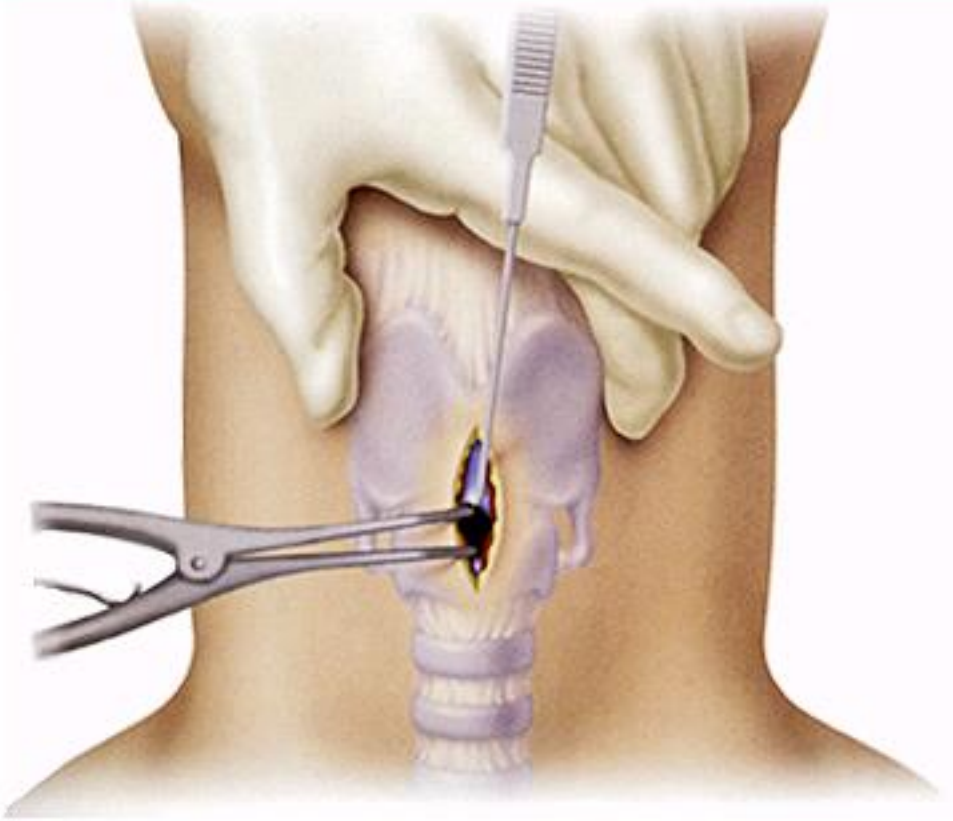

Insert the Trousseau dilator and open to expand the incision vertically.

Reproduced with permission from: Custalow CB. Color Atlas of Emergency Department Procedures, Elsevier Saunders, Philadelphia 2005. Copyright ©2005 Elsevier.

UpToDate®

Copyrights apply

Standard cricothyrotomy step six

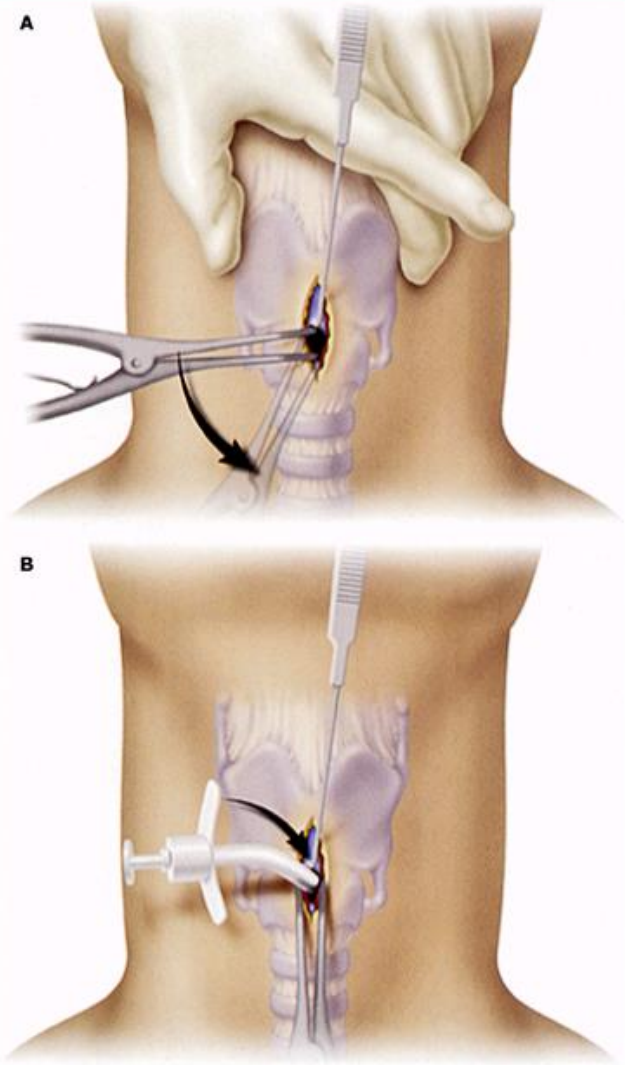

A) Rotate the dilator 90 degrees. B) Insert the tracheostomy tube, and advance the tube into the trachea.

Reproduced with permission from: Custalow CB. Color Atlas of Emergency Department Procedures, Elsevier Saunders, Philadelphia 2005. Copyright ©2005 Elsevier.

UpToDate®

Copyrights apply

Standard cricothyrotomy step seven

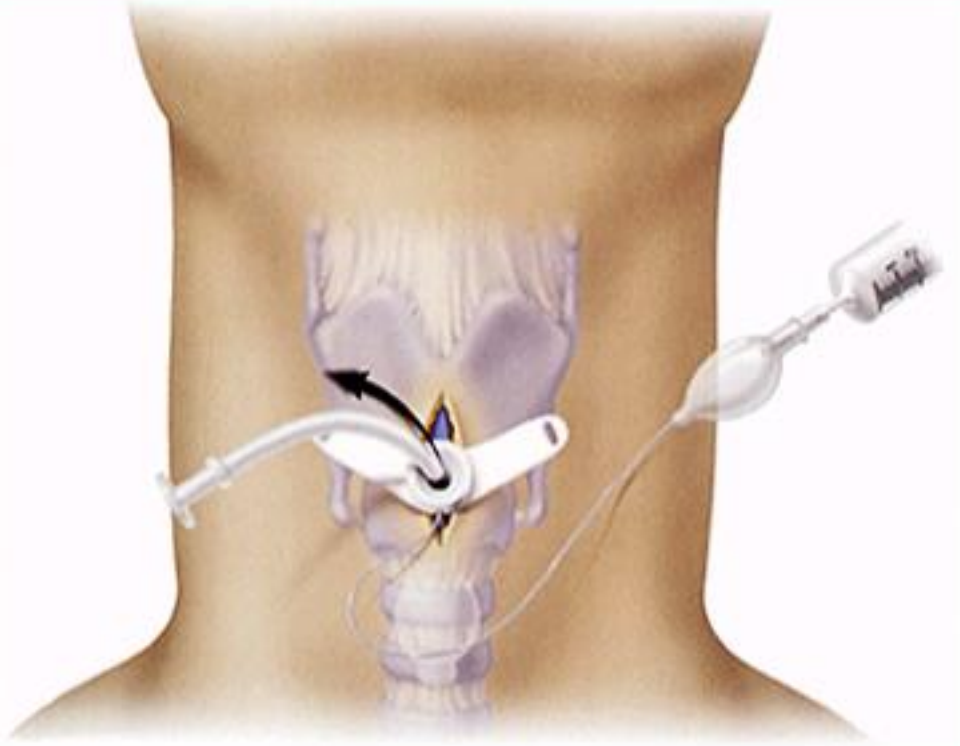

Remove the obturator.

Reproduced with permission from: Custalow CB. Color Atlas of Emergency Department Procedures, Elsevier Saunders, Philadelphia 2005. Copyright ©2005 Elsevier.

UpToDate®

Copyrights apply

Standard cricothyrotomy step eight

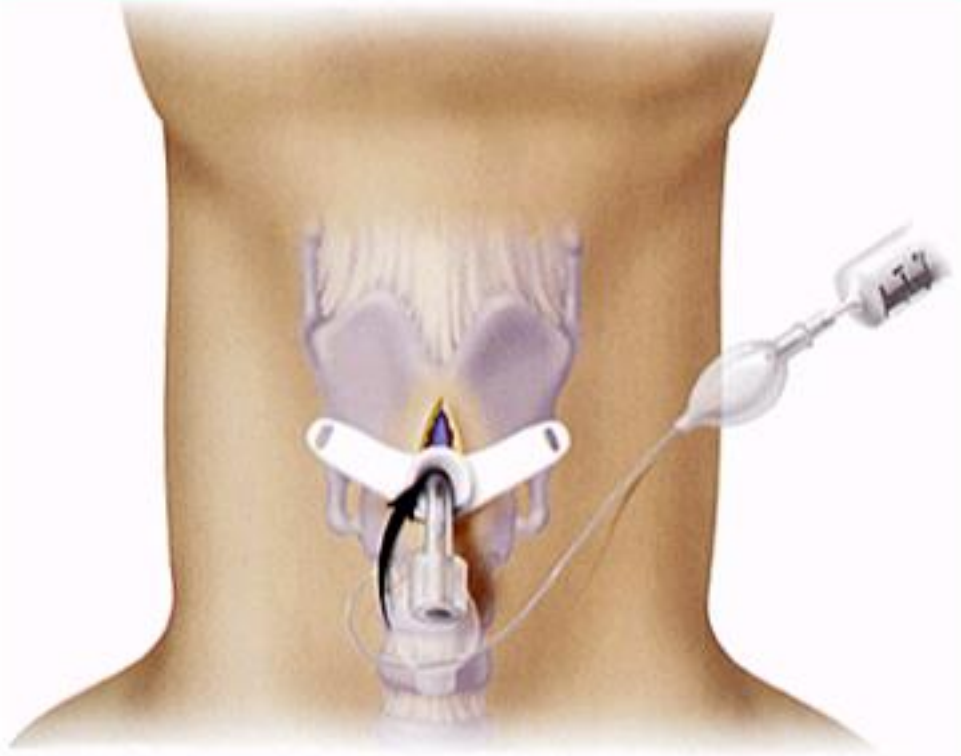

Replace the inner cannula and inflate the cuff.

Reproduced with permission from: Custalow CB. Color Atlas of Emergency Department Procedures, Elsevier Saunders, Philadelphia 2005. Copyright ©2005 Elsevier.

UpToDate®

Copyrights apply

Standard cricothyrotomy step nine

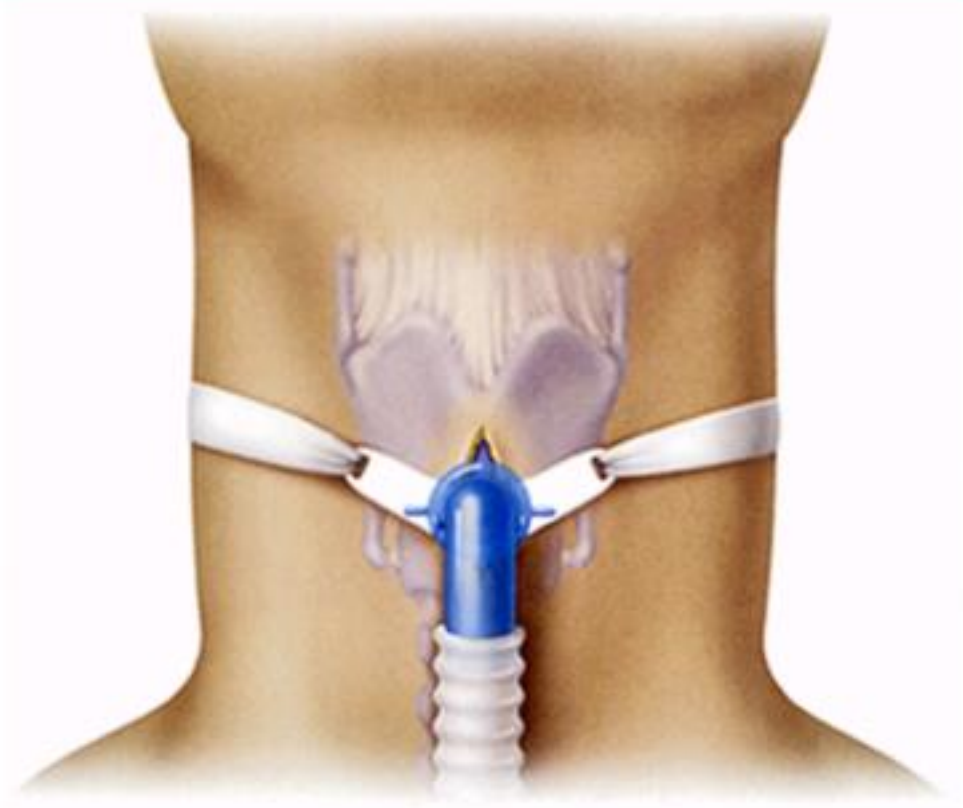

Attach ventilator tubing, confirm proper placement, and secure the tube with a circumferential tie around the patient's neck.

Reproduced with permission from: Custalow CB. Color Atlas of Emergency Department Procedures, Elsevier Saunders, Philadelphia 2005. Copyright ©2005 Elsevier.

UpToDate®

Copyrights apply

Seldinger technique for cricothyroidotomy

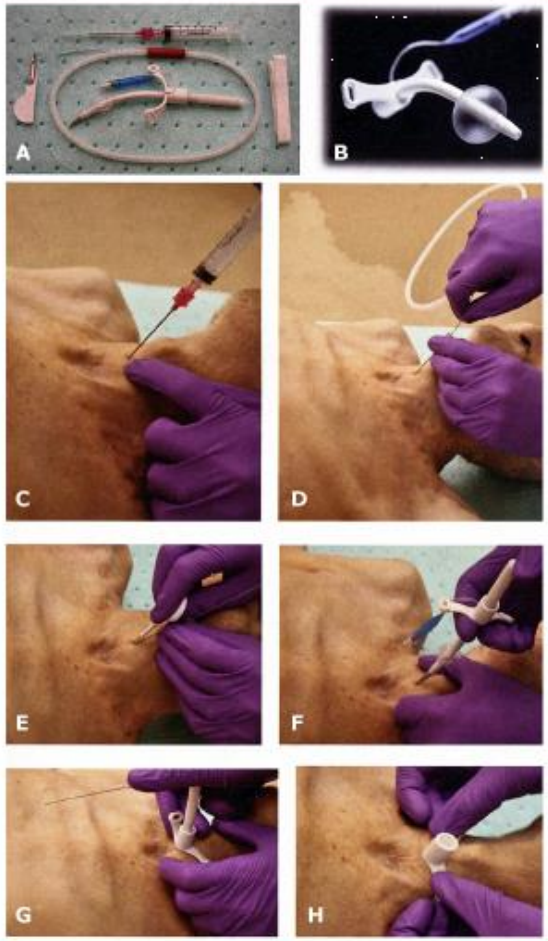

A) Kit contents. B) Cuffed tube. C) Needle insertion. D) Wire placement through needle. E) Small incision. F) Airway with dilator inserted with wire guidance. G) Airway inserted to the hub using a gentle twisting motion. H) Wire and dilator removed as one.

Reproduced with permission from: Walls RM. Manual of Emergency Airway Management. Lippincott Williams & Wilkins, 2008. Copyright © 2008 Lippincott Williams & Wilkins. www.lww.com.

UpToDate®

Copyrights apply